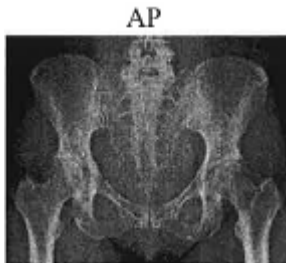


## Pelvis X-ray Guideline

**Routine:** 1 view

- AP with lower extremities internally rotated 15-20 degrees
  - To visualize pelvic pathology, shielding for female patients is not recommended to ensure that anatomy is included.



**Judet view:** 2 views

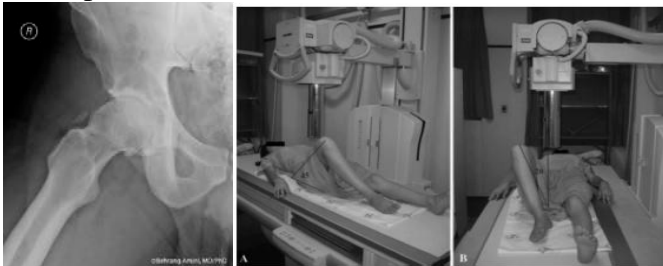- BILATERAL OBLIQUES (45 degrees) – include whole pelvis
- Done for acetabular fractures.

**Pelvic inlet/outlet views:** 2 views

- INLET: 30 degrees caudad angle with CR at pubis
- OULET: 30 degrees cephalic angle with CR at ASIS

**Modified (45 degree) Dunn view:** Used for evaluation of Femoral Acetabular Impingement (FAI)

- Hip is flexed to 45° with the knee bent and the foot flat on the table.



- If requested by the ordering provider, a Modified 90° Dunn View may be performed. This is only to be utilized when specifically requested by the provider and be documented.